Typical idiopathic optic neuritis

Jonathan A. Micieli, MD

Valérie Biousse, MD

A 41 year old white woman presents with right eye blurry vision and pain with eye movements for one week

Visual acuity: 20/150 OD, 20/20 OS

Right RAPD

Color vision: control plate not seen OD, 14/14 correct Ishihara color plates OS

Figure 1

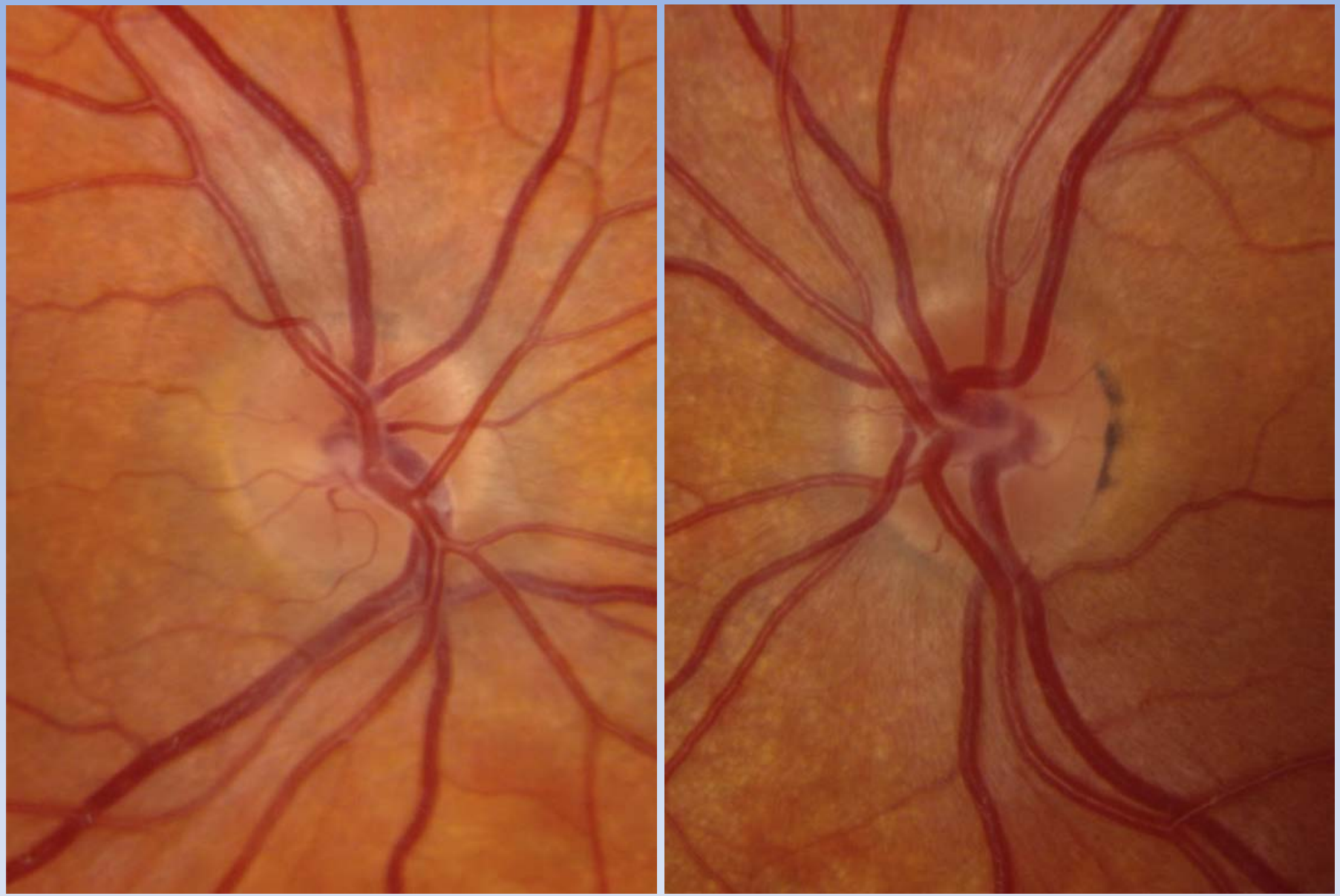

Right eye

Left eye

Figure 1

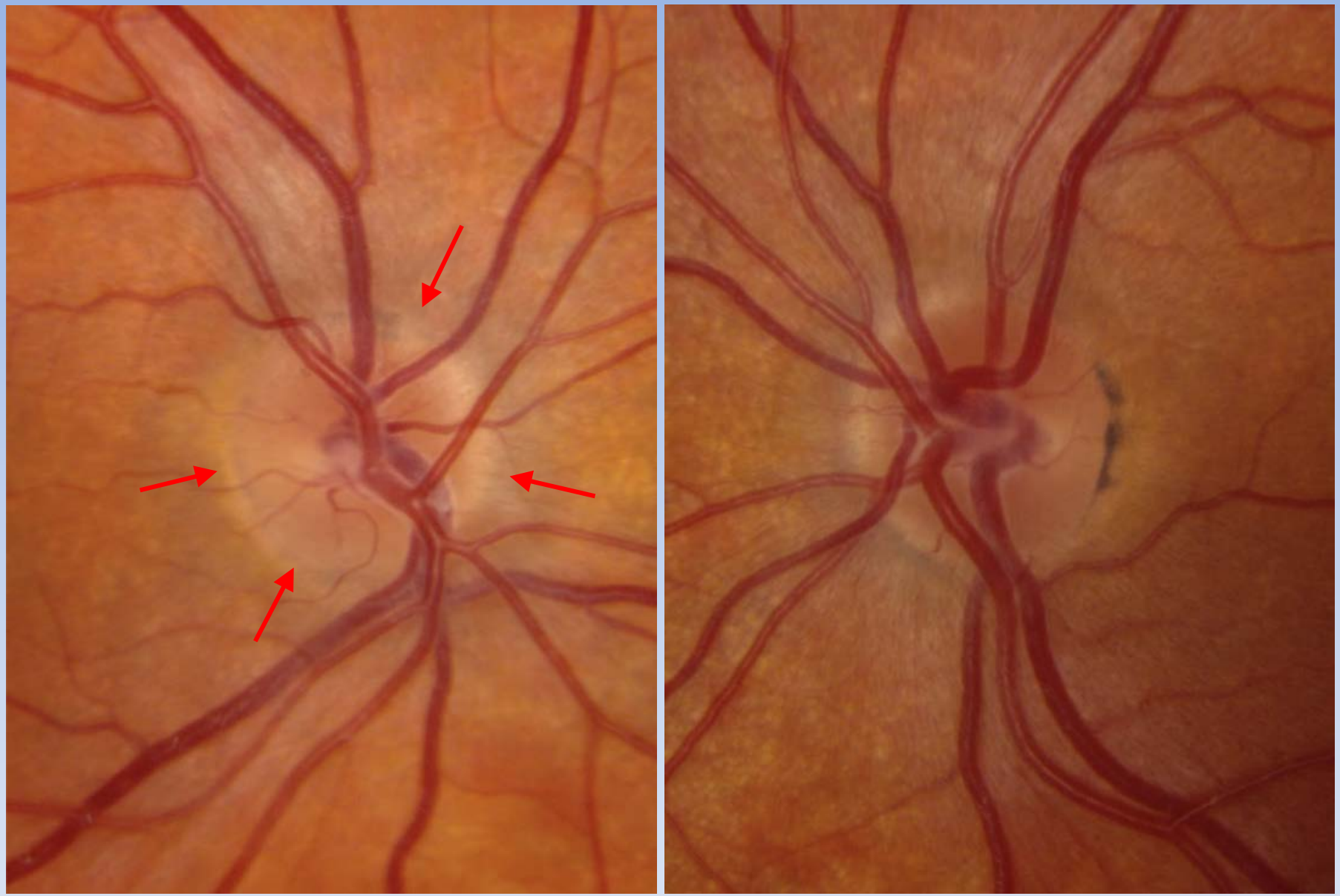

Right eye

Left eye

There is subtle hyperemia of the right optic nerve (red arrows)

Figure 2

Retinal nerve fiber layer (RNFL) analysis

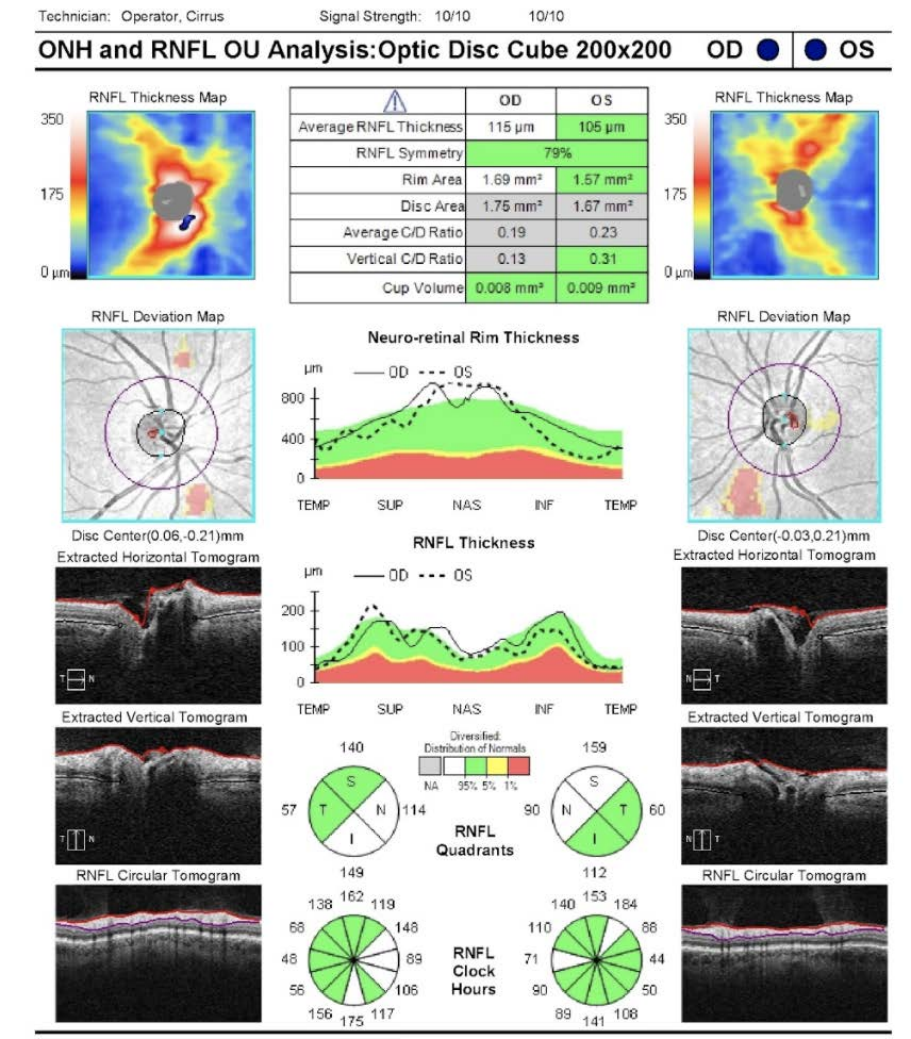

Ganglion cell layer (GCL) analysis

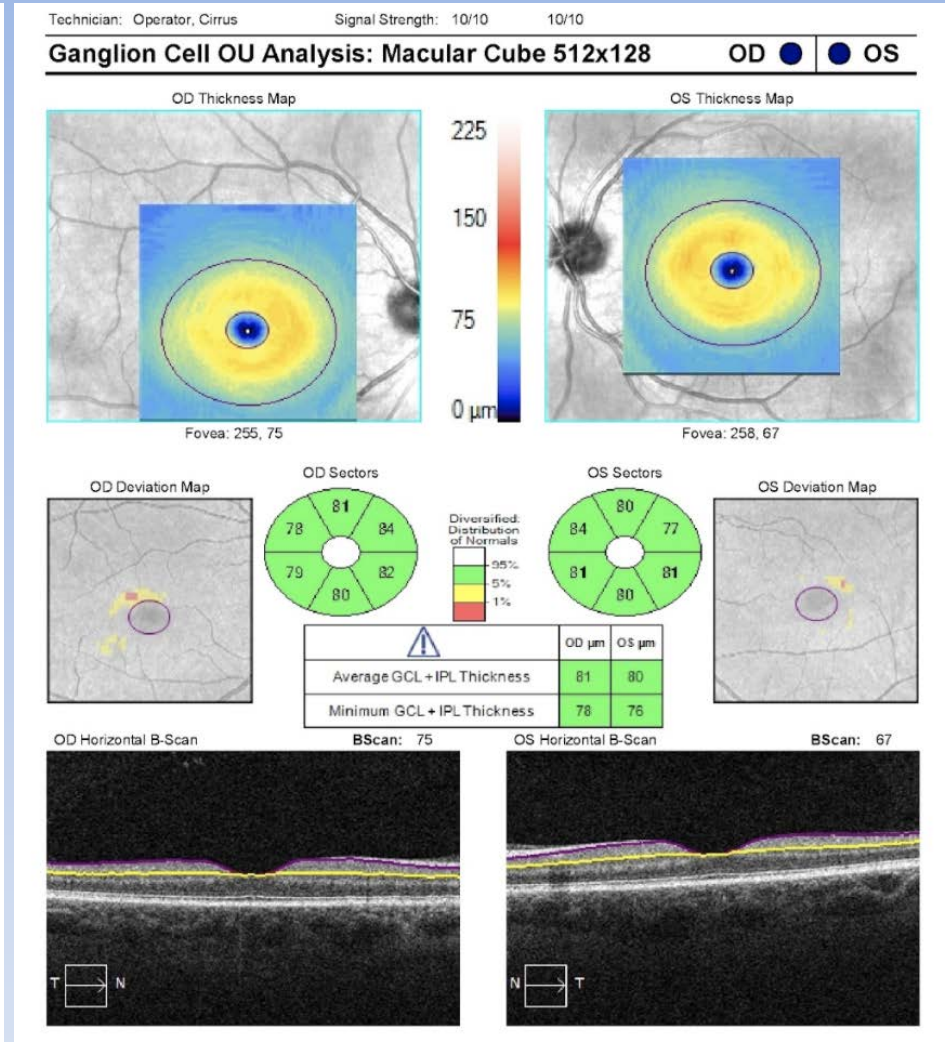

Figure 2

Retinal nerve fiber layer (RNFL) analysis

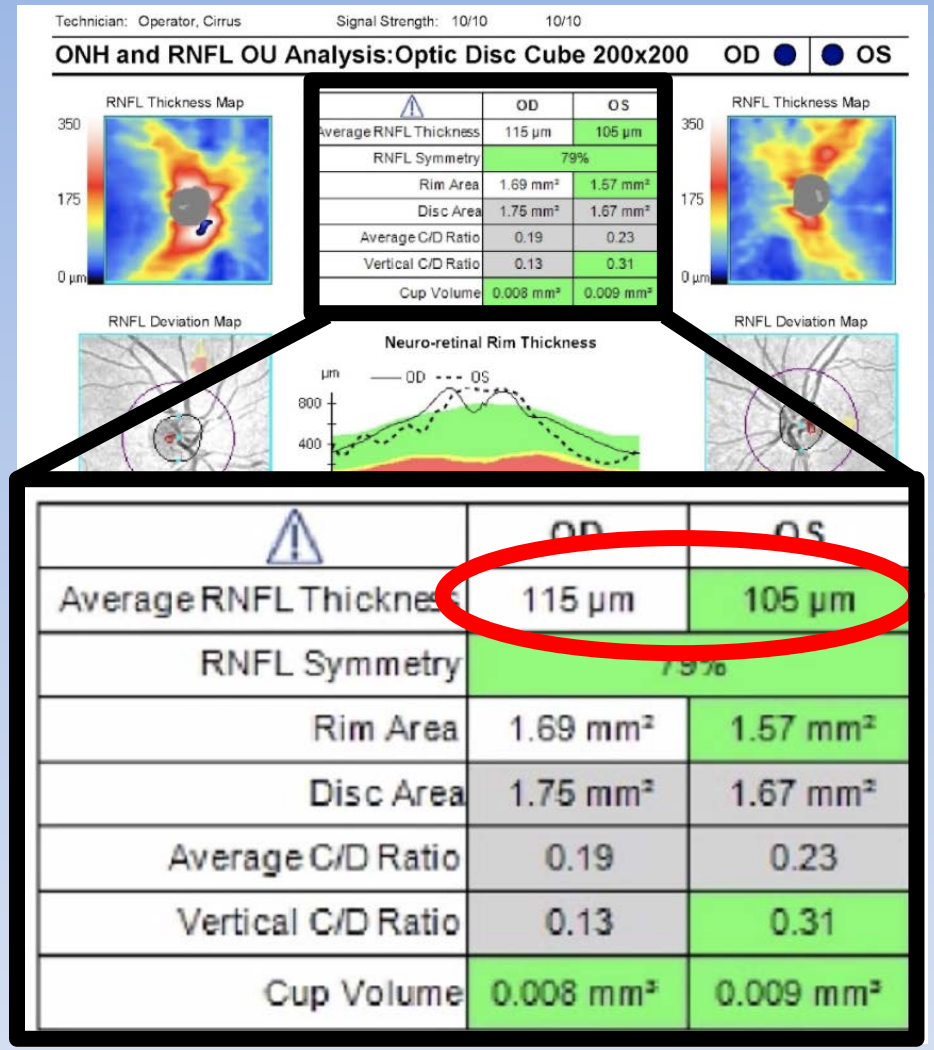

Ganglion cell layer (GCL) analysis

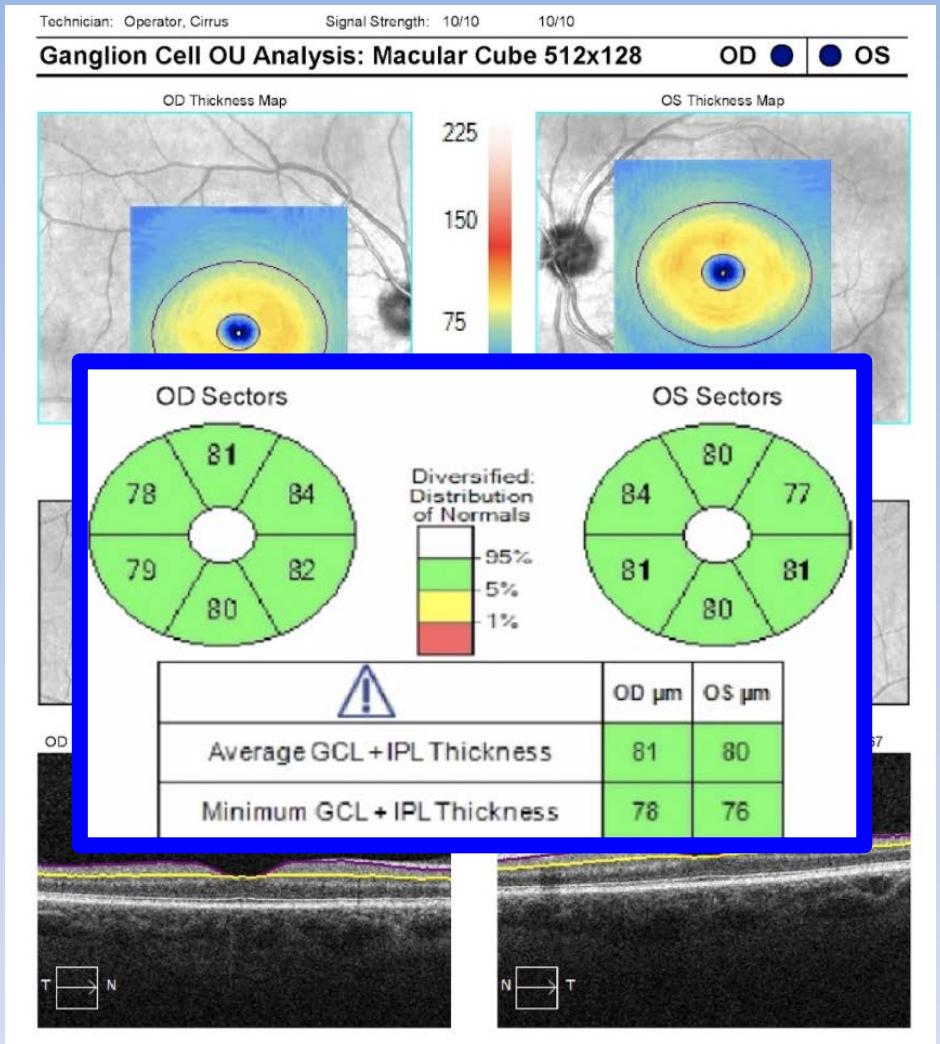

Cirrus optical coherence tomography (OCT) of the retinal nerve fiber layer (RNFL) is mildly elevated in the right eye (red circle) and the ganglion cell layer (GCL) thickness is normal (blue box).

Figure 3

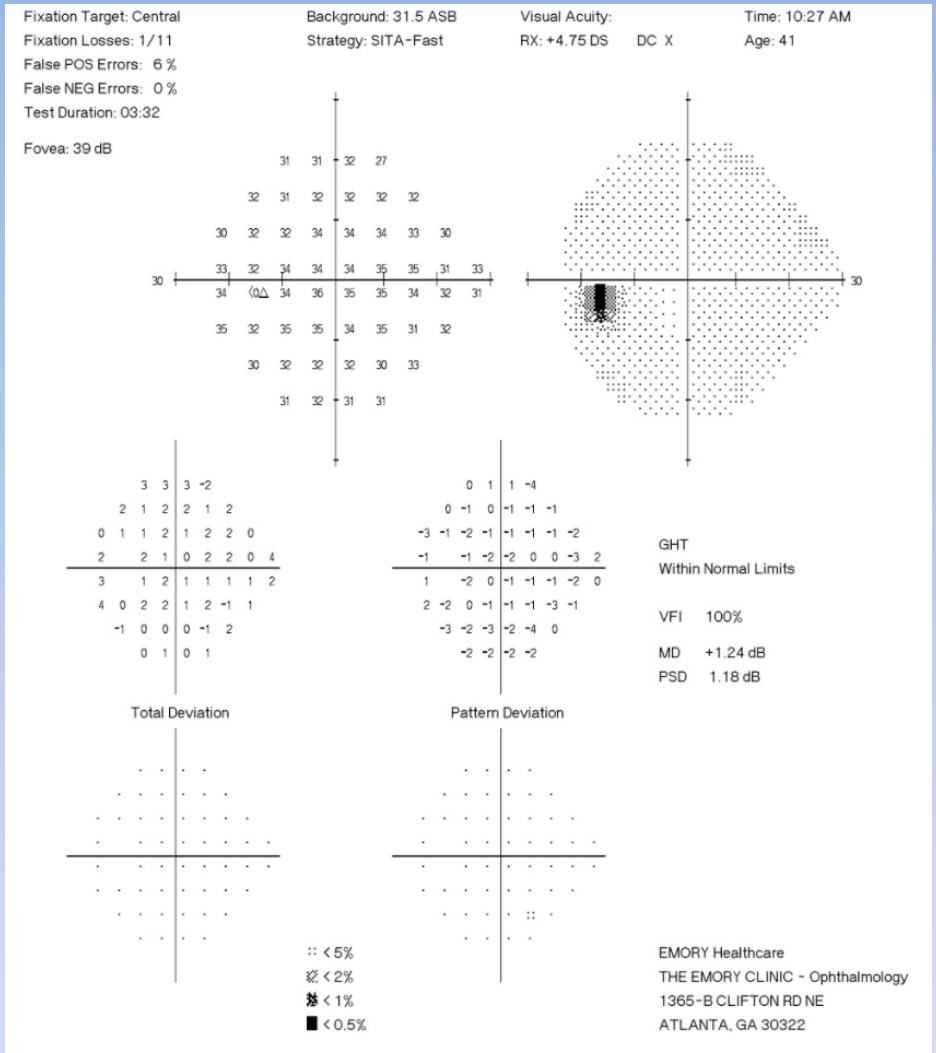

Left eye

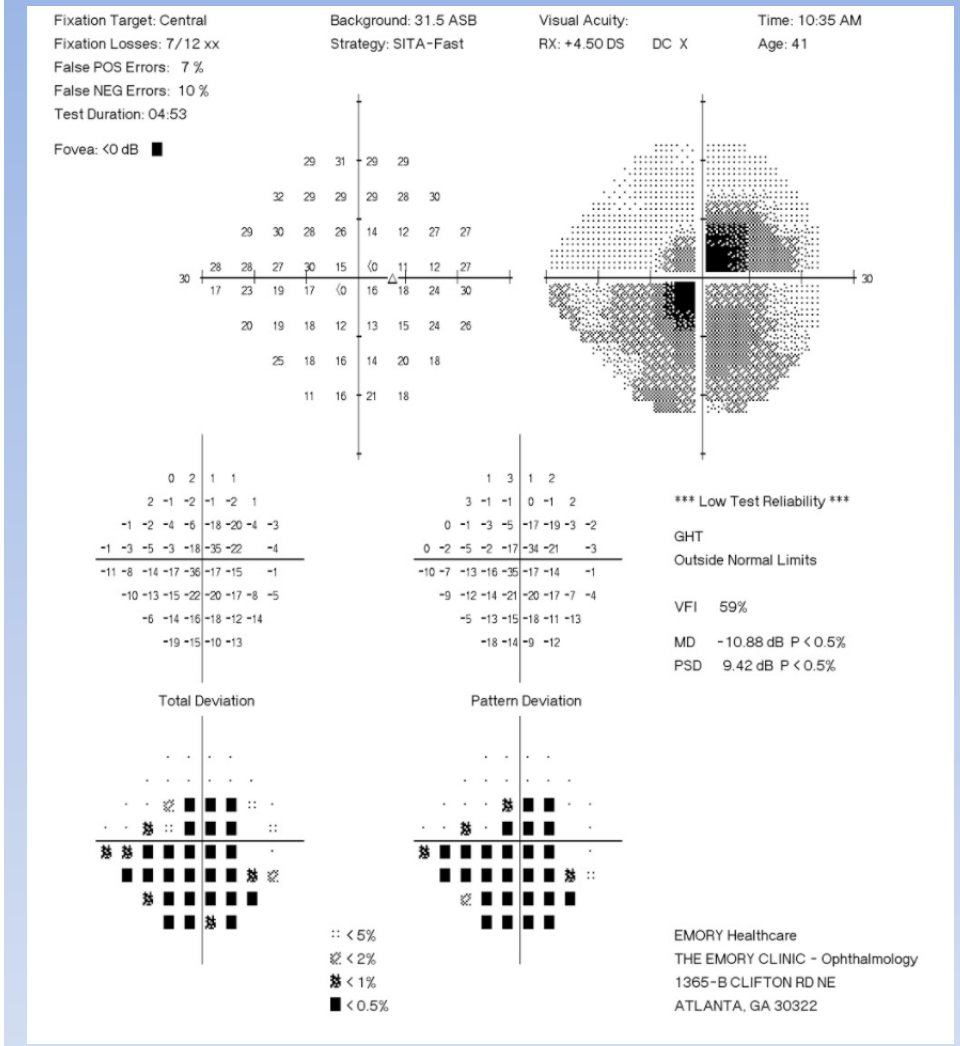

Right eye

Humphrey visual fields show a cecocentral scotoma in the right eye

Axial MRI of the orbits with contrast (T1 with fat suppression) shows enhancement of the right intraorbital optic nerve (red arrow)

Figure 5

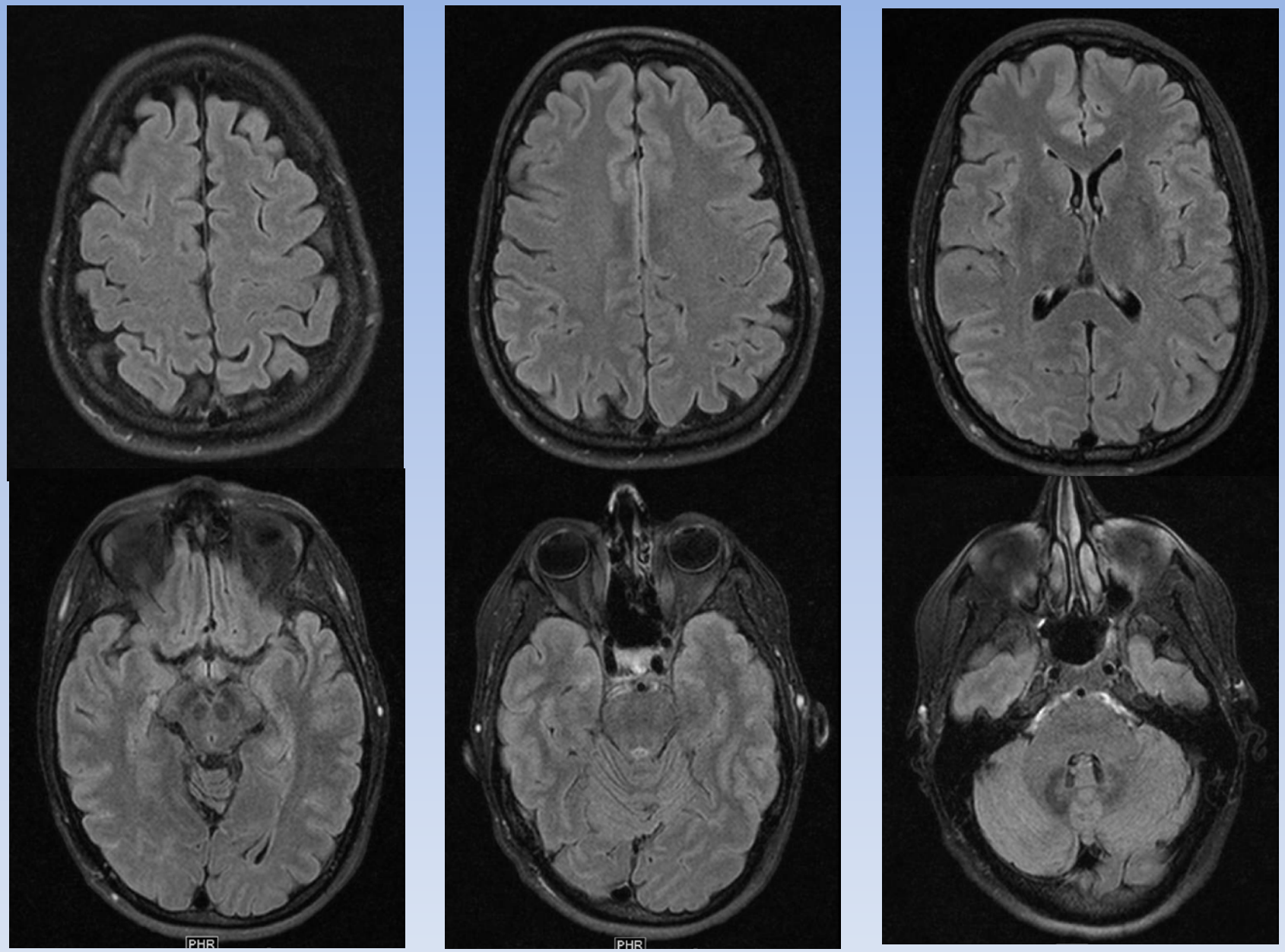

MRI of the brain and spine were normal (FLAIR images shown here) without white matter lesions

She was treated with intravenous methylprednisolone 1 gram per day for 3 days followed by oral prednisone (similar to the Optic Neuritis Treatment Trial)

She felt her vision returned close to baseline after about 6 weeks

At her 6 month follow-up:

VA 20/15 OD, 20/15 OS

No RAPD

Color vision 14/14 OD, 14/14 OS correct Ishihara color plates

Figure 6

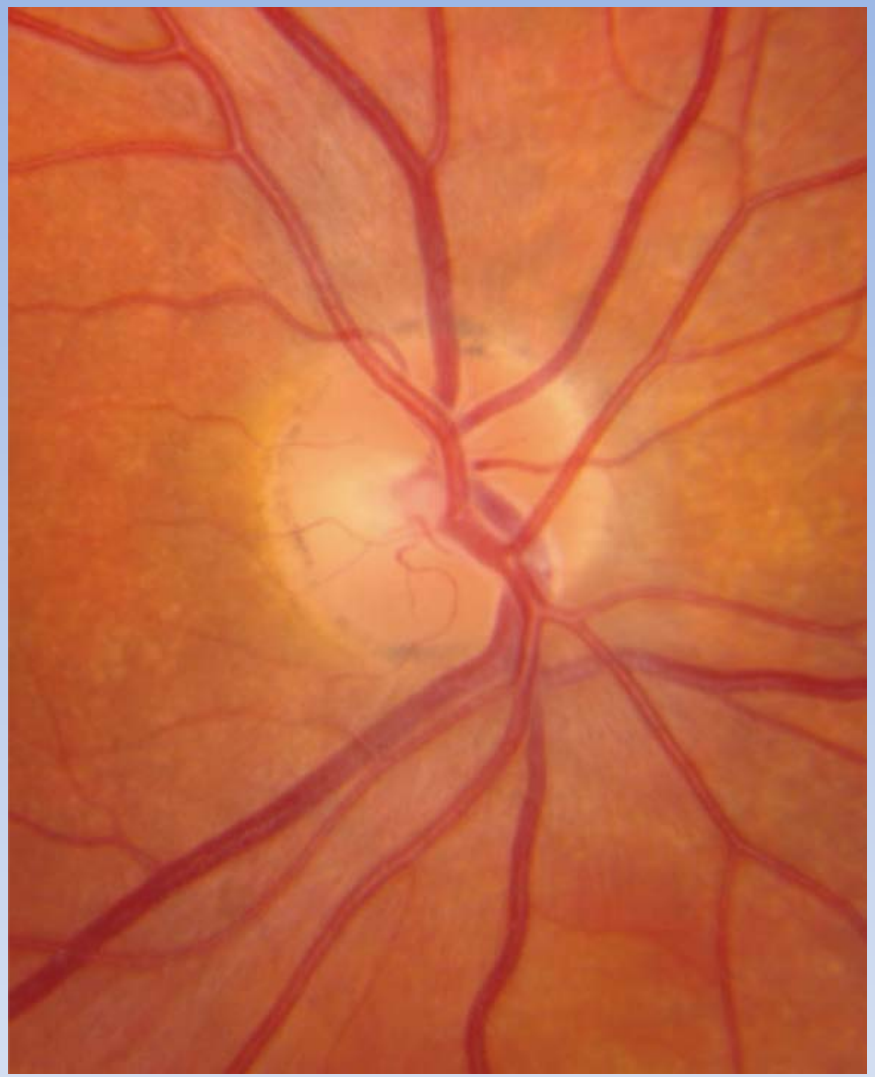

Right eye

Left eye

Fundus 6 months after an episode of optic neuritis in the right eye

Figure 6

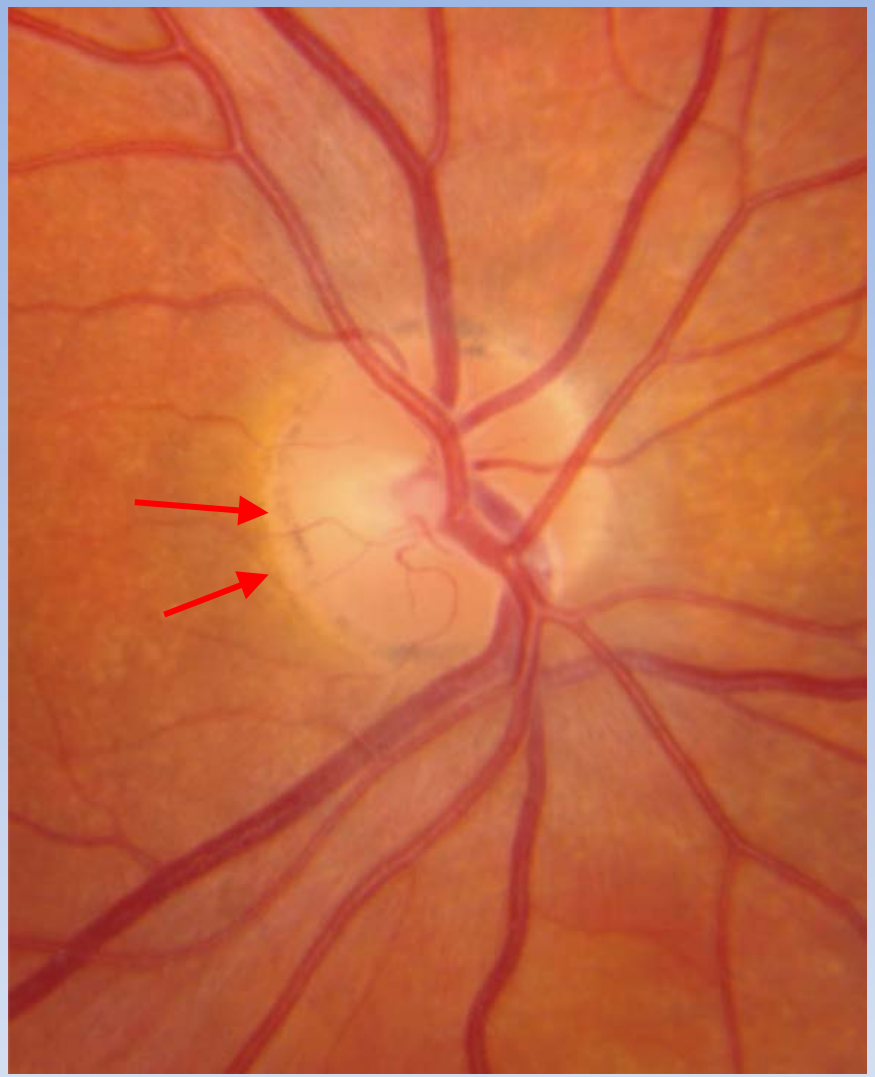

Right eye

Left eye

There is temporal pallor of the right optic disc (red arrows)

Figure 7

Retinal nerve fiber layer (RNFL) analysis

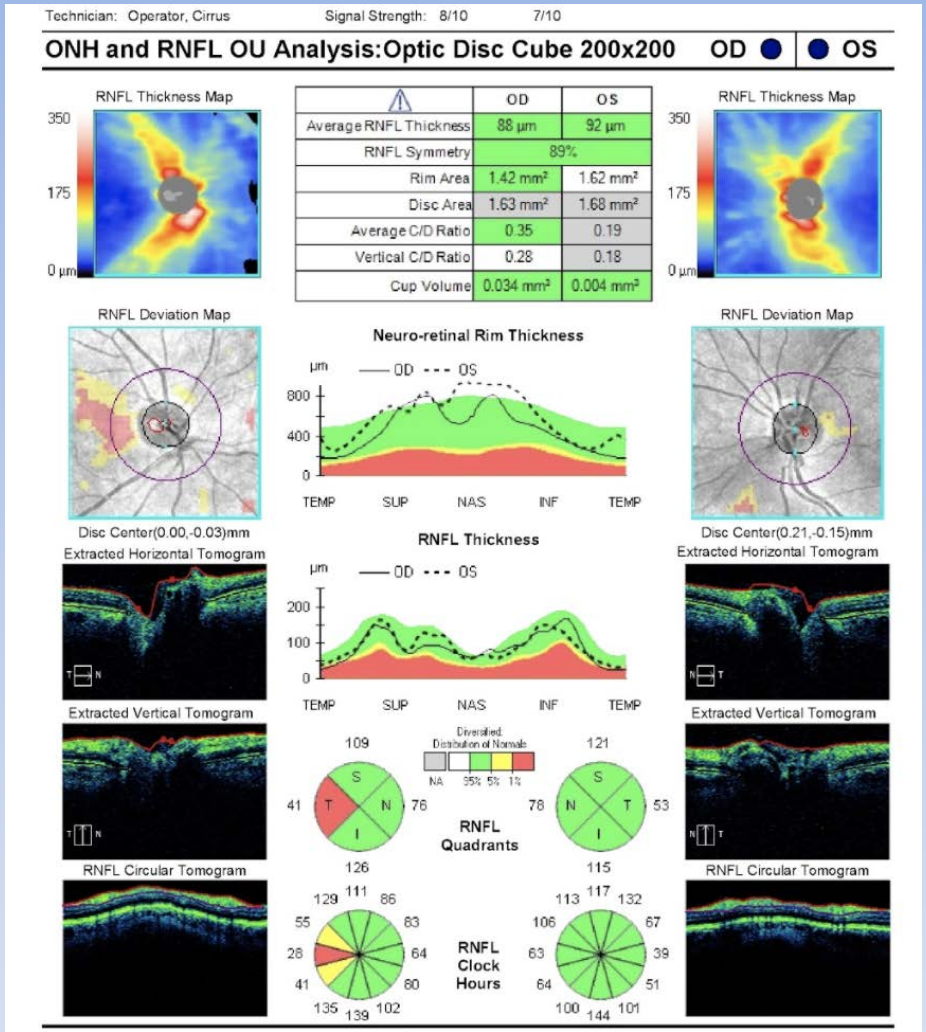

Ganglion cell layer (GCL) analysis

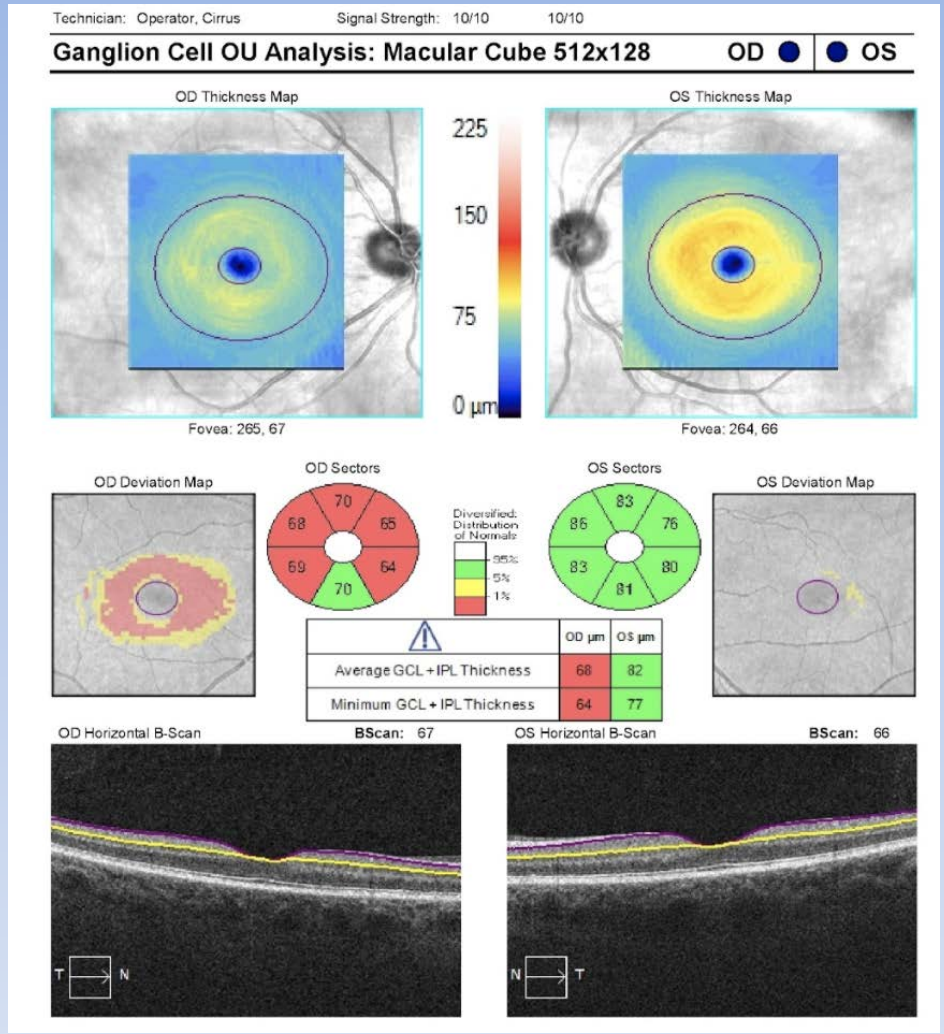

Cirrus OCT 6 months after an episode of optic neuritis in the right eye

Figure 7

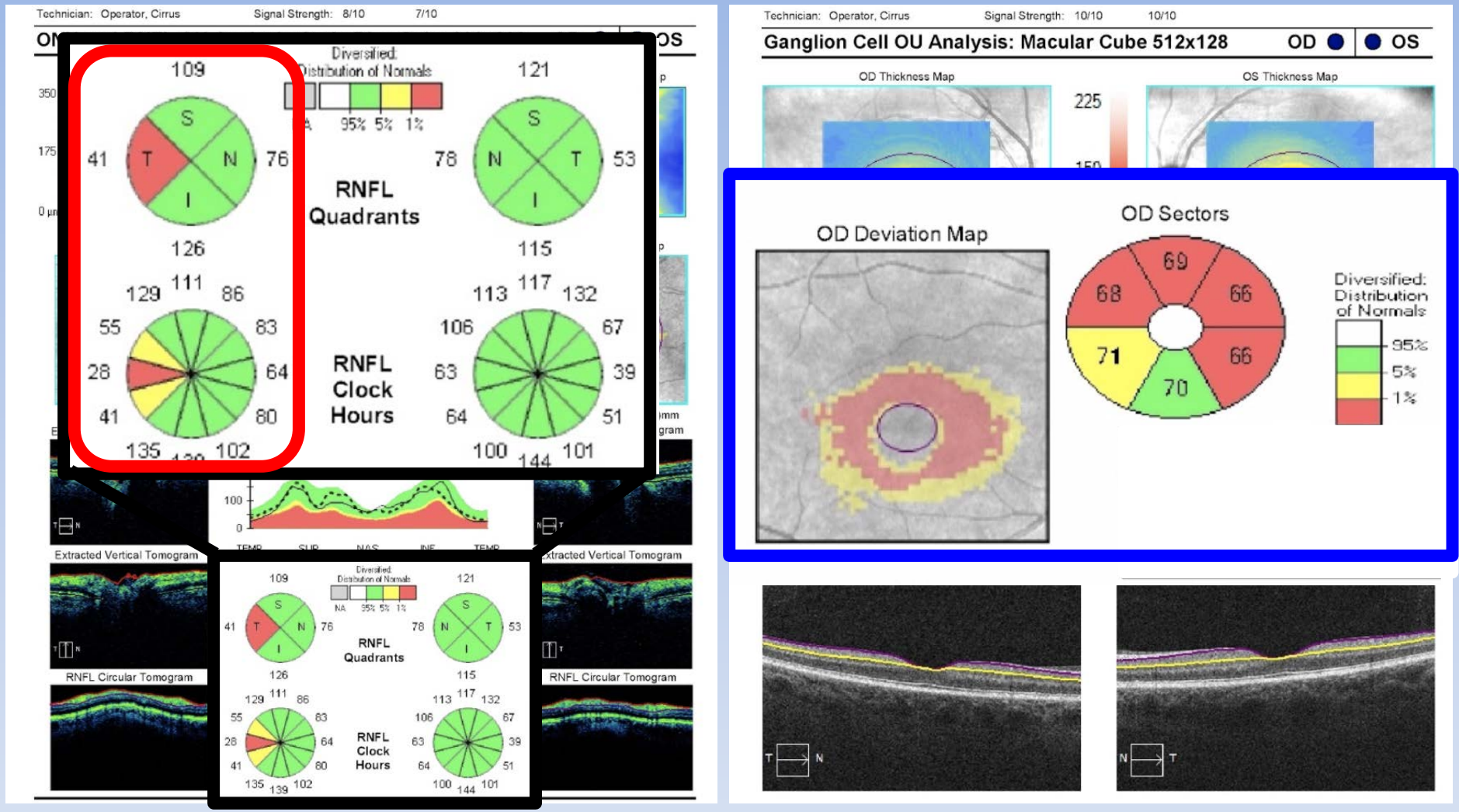

There is temporal thinning of the RNFL (red circle) and a reduction in macular GCL thickness on OCT (blue square) in the right eye. Red areas indicate a thickness seen in less than 1% of the normal population.

Figure 8

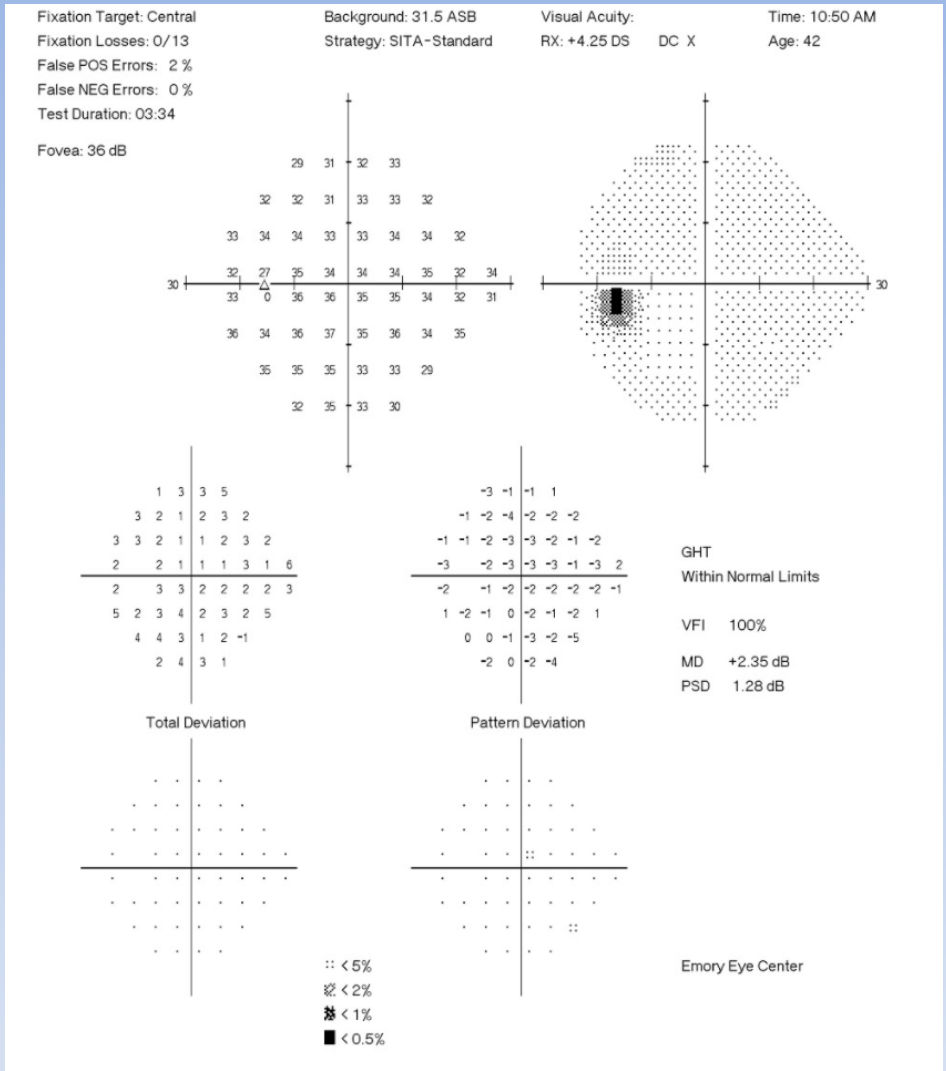

Left eye

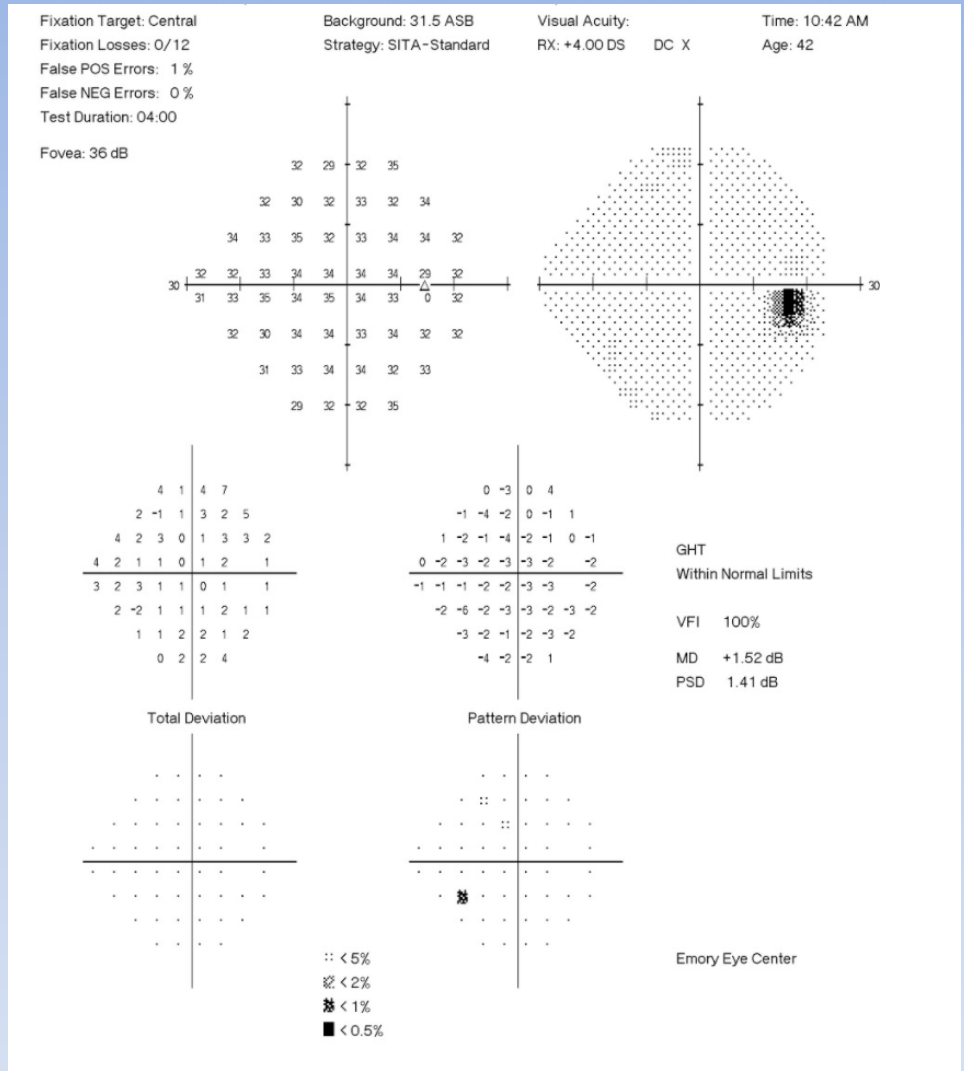

Right eye

24-2 SITA Fast Humphrey visual fields were normal in both eyes

Figure 9

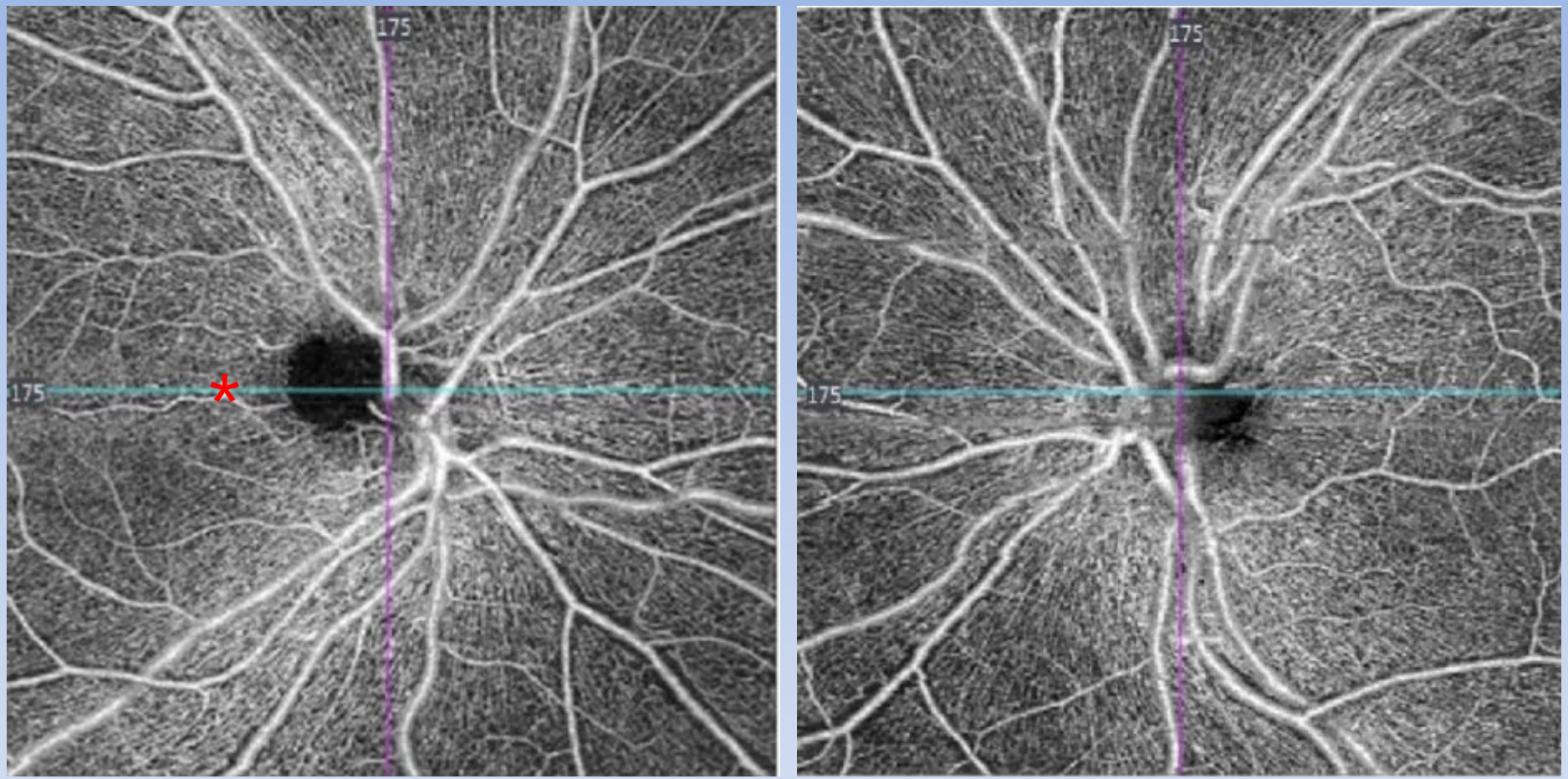

Cirrus OCT angiography of the superficial vascular plexus shows reduction in the peripapillary capillary network temporally in the right eye (red star), corresponding to the area of RNFL thinning. OCT angiography was not necessary for the follow-up of this patient, but was available for review.

Summary points:

- **Typical features** of optic neuritis seen in this case:
  - young or middle age woman
  - pain with eye movements
  - absent or mild disc edema
  - recovery of vision

- Because her MRI of the brain was normal, her 15-year risk of multiple sclerosis is 25% based on the ONTT[1]

- **Atypical features** of optic neuritis that should prompt further workup include:
  - older age
  - absence of pain
  - bilateral or rapidly sequential vision loss
  - no recovery of vision or rapid recovery of vision with steroids
  - retinal hemorrhages or vitreous inflammation

[1]Arch Neurol. 2008;65(6):727-732